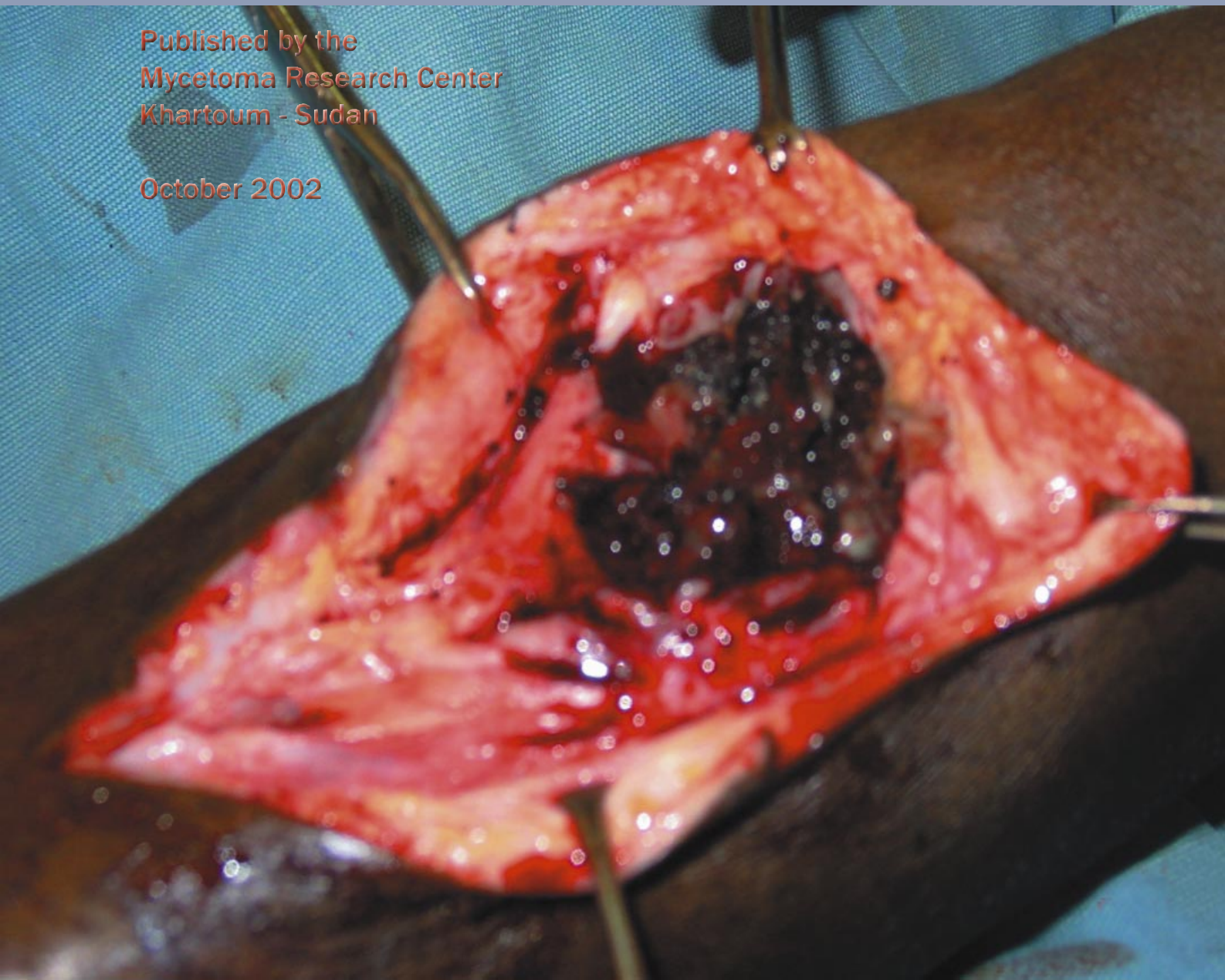

Evidence-Based Guidelines for the Management of Mycetoma Patients

Published by the
Mycetoma Research Center
Khartoum - Sudan

October 2002





A Ward in the Mycetoma Research Center at Soba University Hospital



The Mycetoma Clinic at Soba University Hospital



Evidence-Based Guidelines for the Management of Mycetoma Patients

Mycetoma is a chronic granulomatous, progressive inflammatory disease that involves the subcutaneous tissue after a traumatic inoculation of the causative organism. It may be caused by true fungi (eumycetes) or by higher bacteria (actinomycetes) and therefore it is classified into eumycetoma and actinomycetoma respectively. The characteristic triad of a painless subcutaneous mass, sinuses and the discharge of grains is pathognomic of mycetoma. The lesion usually presents as a slowly progressive painless swelling at the site of previous trauma and gradually increases in size. It may spread to involve the skin and deep structures resulting in destruction of bone, deformity and loss of function with serious social and economic implications. As mycetoma has a progressive course, it needs a long time to be cured, with a high recurrence rate, mycetoma patients preferably should be treated in a specialized clinic, the mycetoma clinic.



Professor Ahmed Hassan Fahal

on behalf of the

*Mycetoma Research Centre,
University of Khartoum,
PO Box 102 Khartoum, Sudan
www.mycetoma.org*

The Mycetoma Clinic

Mission

- √ *Maintenance of the highest standards of patient management.*
- √ *Standardization of the diagnostic tools.*
- √ *Standardization of the treatment of patients.*
- √ *Maintenance of patients follow-up.*
- √ *Establishment of the teamwork approach for management.*

Clinic Members

The members of the clinic include, general and orthopedics surgeons, pathologist, radiologist, mycologist, psychiatrist, pharmacist, physiotherapist, counseling nurse, secretary, social worker and paramedical staff.

The clinic team usually hold weekly meeting for fast and reliable means of communication and information exchange about the individual patients and to plan management.

*Some Patients In
The Mycetoma
Clinic Waiting
Area*



Radiology:

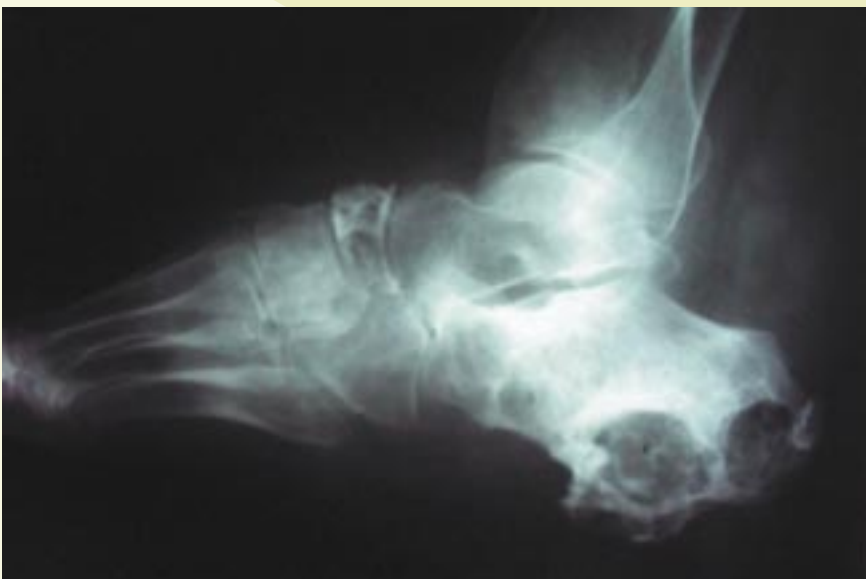Many radiological changes are seen in mycetoma. These include:

1- Soft tissue granuloma, which appears as a dense shadow or as scattered multiple soft tissue shadows with calcification and obliteration of the fascial planes. The cortex may be compressed from outside by the granuloma leading to bone scalloping.

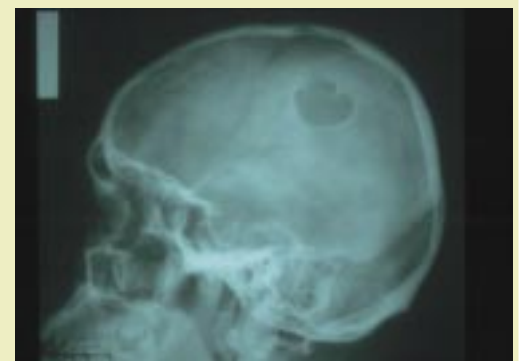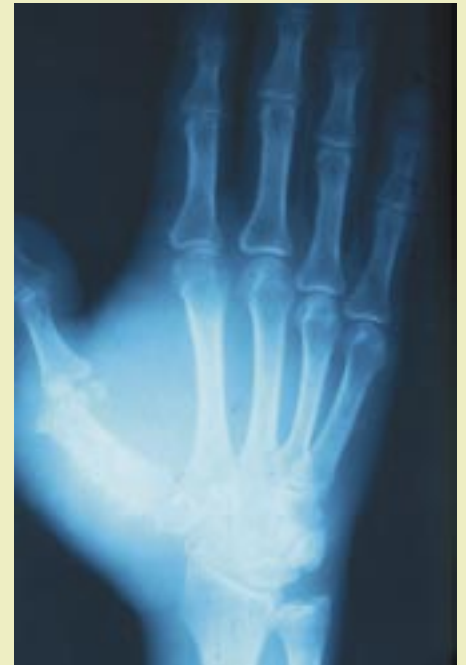2- When the bone is involved there may be a periosteal reaction. This will lead to the formation of sun-ray appearance and Codman triangle, an appearance that may be indistinguishable from that of osteogenic sarcoma.

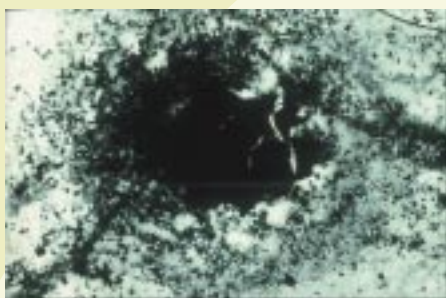
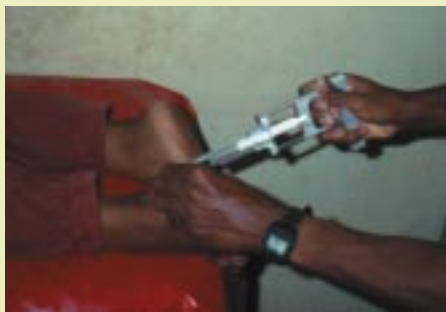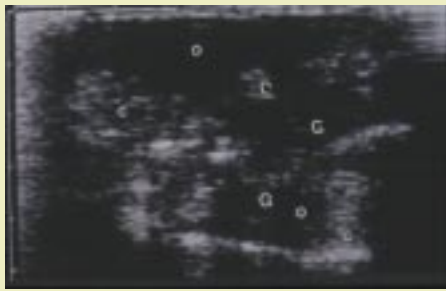
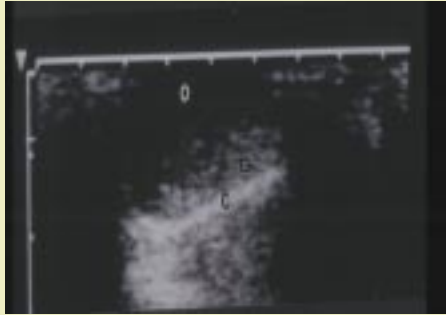
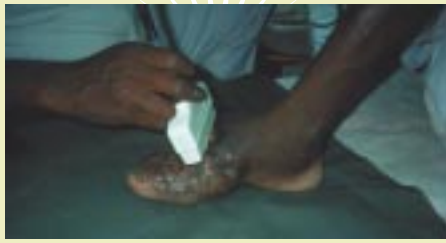3- Formation of cavities that may be multiple punched out through out an otherwise bone of normal density. These cavities are large in size, few in number with well-defined margins in eumycetoma. The cavities in actinomycetoma are usually smaller in size, numerous and have no definite margins.

In the skull, the bone changes are purely sclerotic with dense bone formation and loss of trabeculation. Osteoporosis at and distal to the affected part is sometime observed in mycetoma and this may be due to disuse atrophy or to compression of the bone and its blood supply by the mycetoma granuloma. Chemotherapy causes radiological improvement consisting of remoulding, absorption of the sclerotic bone and reappearance of the normal trabecular pattern.



Recommended Diagnostic Investigations





Ultrasonic Imaging Of Mycetoma:

Mycetoma has a characteristic ultrasonic appearance. Ultrasound imaging can differentiate between eumycetoma and actinomycetoma and between mycetoma and other non-mycetoma lesions. In eumycetoma lesions, usually there are numerous, isolated sharp bright hyperechoic echoes corresponding to the grains in the lesion. Single or multiple thick walled cavities with no acoustic enhancement are commonly identified and the cavities may contain debris and filaments.

In actinomycetoma lesions the findings are similar but the grains are less distinct. This may be due to their smaller size and consistency, individual embedding of the grains or the absence of the cement substances in some species. The echoes are commonly settled at the bottom of the cavities.

The technique is safe, simple, accurate and useful in planning surgical treatment.

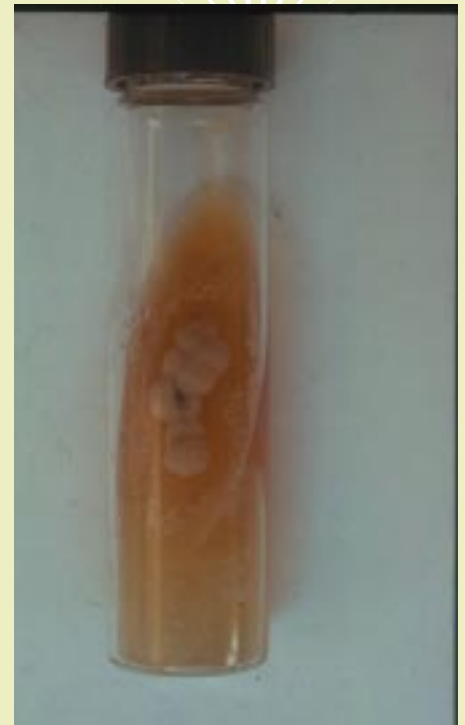Fine Needle Aspiration Cytology Of Mycetoma:

Mycetoma can be accurately diagnosed by Fine Needle Aspiration cytology (FNA). Mycetoma lesion has a distinct appearance in a cytology smear characterised by the presence of polymorphous inflammatory cells consisting of an admixture of neutrophils, lymphocytes, plasma cells, histiocytes, macrophages and foreign body giant cells and grains. In sections, the grain is closely surrounded by and occasionally infiltrated by neutrophils causing its fragmentation. Outside the neutrophil zone, monocytic cells and giant cells are seen. This is surrounded by granulation tissue rich in fibroblasts and blood vessels. FNA allows morphological identification of mycetoma and its classification into eumycetoma and actinomycetoma. This is important as the treatment depends mainly on the aetiological agents.

The technique is simple, cheap, rapid, and sensitive and can be tolerated by patients. It can be used for diagnosis, collection of material for culture and immunological studies and for mycetoma epidemiological surveys.

Culture:

The mycetoma causative organisms can be identified by their textural description, morphological and biological activities in pure culture. The biological activity may include acid fastness, optimal temperature, proteolytic activity, utilization of sugars and nitrogenous compounds. The grains are the source of the culture and they should be alive and free of contaminants and they are usually obtained by deep surgical biopsy. Grains should be sent immediately in sterile containers to the laboratory for culture. Many culture media are in use; they include Sabouraud, blood agar and Malt extract agar. Although culture is the gold standard in the diagnosis of mycetoma, the technique is cumbersome, time consuming and chance contamination may give a false positive result. It also requires experience to identify the causative organisms.



The Histological Diagnosis:

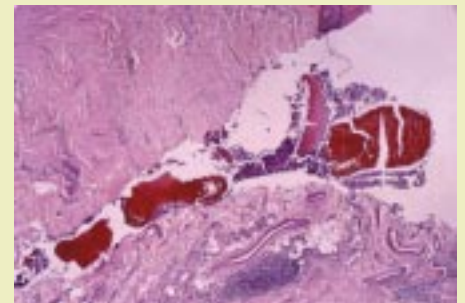
Stained sections usually show the grain morphology and the tissue reaction to the organisms. There are three types of tissue reactions:

Type I: The grain is surrounded and sometimes invaded by an intense neutrophil polymorphonuclear leucocyte infiltrate.

Type II: There is a vascular layer containing macrophages, lymphocytes, plasma cells and giant cells. The giant cells usually contain fragments of the grain. Some macrophages may have a foamy cytoplasm.

Type III: Formation of pure epithelioid granuloma.

The technique is attractive in that it requires neither aseptic procedure nor the rigid time schedule required for culture, however it lacks the precision of culture and it needs deep surgical biopsy which may enhance the spread of the organism. Biopsies are usually fixed in 10% formal-saline.



Serodiagnosis in mycetoma:

Serodiagnosis is of a great help in identification and classification of the various organisms, which is an essential prerequisite for medical treatment, and is mandatory for the follow-up of these patients. The common serodiagnostic tests for mycetoma are:

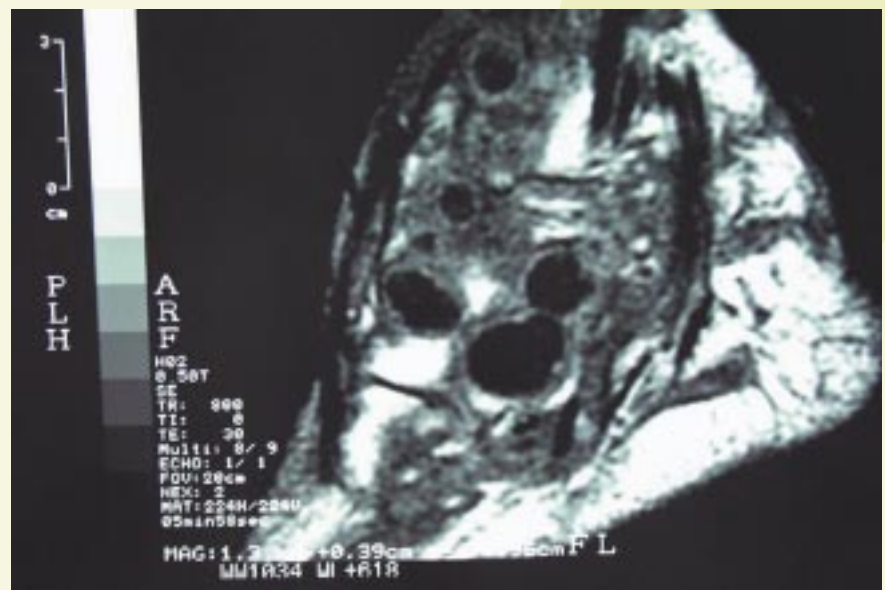
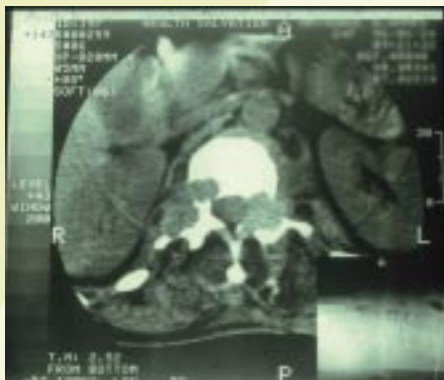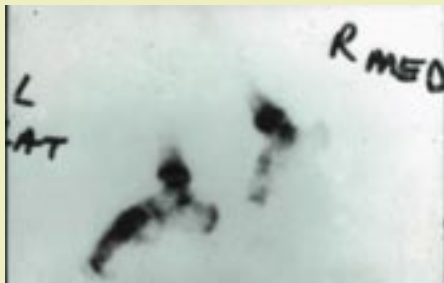
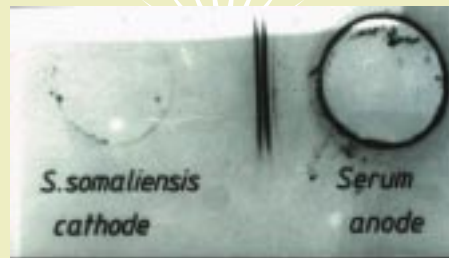1. Counter-immuno-electrophoresis (CIE)
2. Immunodiffusion (ID)
3. Enzyme linked immunosorbent assay (ELISA)

These tests are not sensitive enough and unless antigens are quite pure, it can be negative in early cases. They are simple, economical but are time consuming and there is cross-reactivity between the individual organisms. (ELISA) appears to be a sensitive test for the detection of antibodies. However the high sensitivity of the test makes the cross reactivity unavoidable. ELISA may be a useful tool in community sero-epidemiological surveys.

Bone Scan, CT Scan and MRI

Other modalities which may come in handy on occasion in the investigation of mycetoma lesions are the use of bone scanning, computerized tomography and magnetic resonance imaging.

Although currently their use is limited by their availability and expense, but none-the-less they may be used successfully for diagnosis or planning of surgical management in particular.



The treatment of mycetoma depends mainly on its aetiological agent and the extent of the disease. Until recently, in many centres, the only available treatment for mycetoma was amputation or mutilating surgical excision of the affected part.

The Treatment of Mycetoma

Treatment of Actinomycetoma:

Actinomycetoma is amenable to medical treatment with antibiotics and other chemotherapeutic agents. Combined drug therapy is always preferred to a single drug to avoid drug resistance and to eradicate residual infection.

The common drugs regimes are:


1. Streptomycin sulphate (14 mg/kg daily) and Diaminodiphenyl sulphone (dapson) (1.5 mg/kg twice daily). If there is no response for few months or if there is persistent side effects then dapsone is replaced by Co-trimoxazole (14 mg/kg twice daily) or Rifampicin (15-20 mg/kg daily).

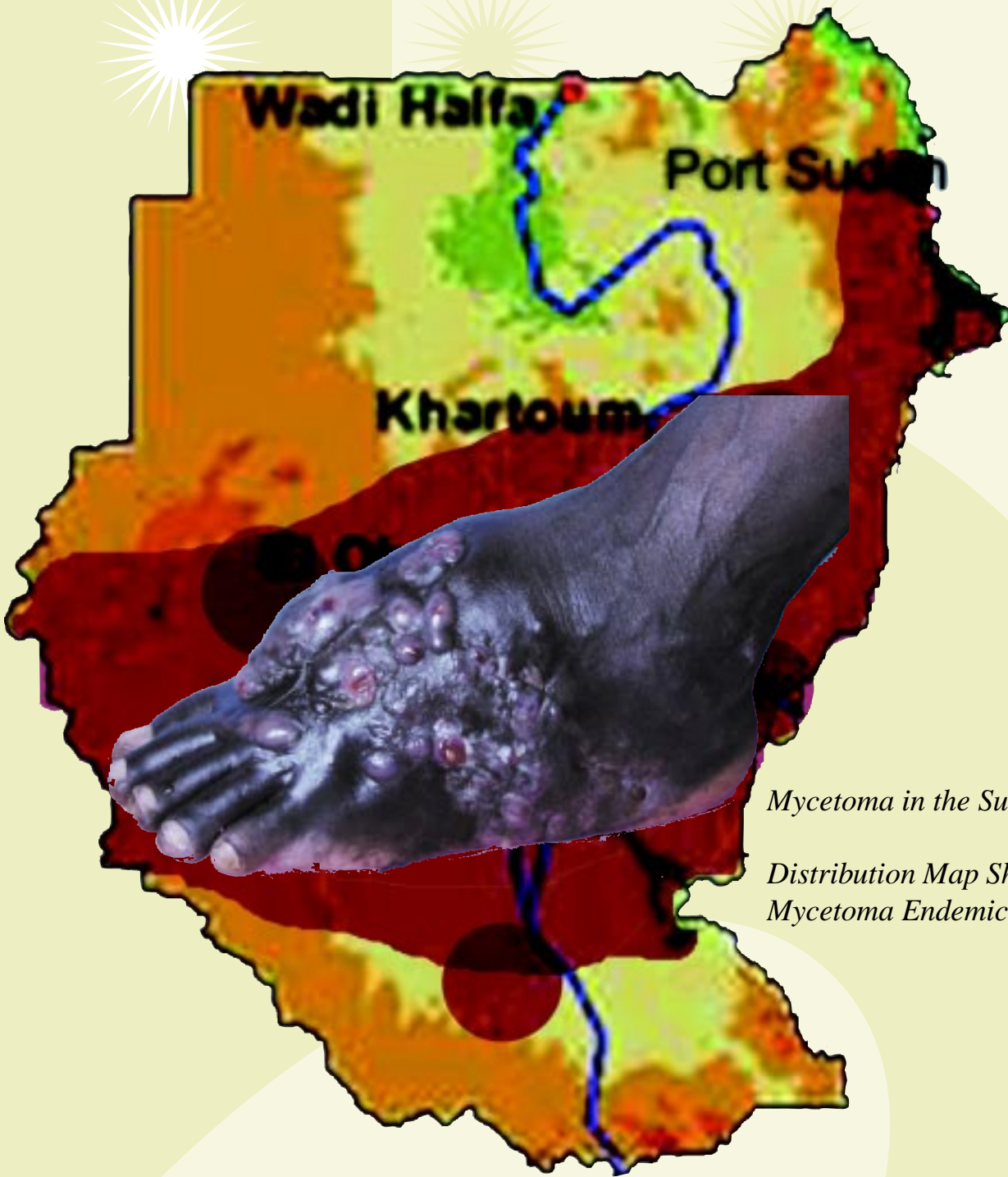
2. Amikacin sulphate (mg/kg) alone or in combination with Co-trimoxazole (14 mg/kg twice daily) is a second line for mycetoma treatment.

In resistant cases other drugs can be used and this includes:

1. Sulfadoxine-pyrimethamine (fansidar)
2. Sulphonamides

Treatment must be continued until the patient is cured. The mean duration of treatment is usually more than one year. Medical treatment should be given pre and post operatively as it facilitates surgery, accelerates healing and reduces the chance of relapse. Medical treatment is useful in all stages of actinomycetoma even with advanced disease. The cure rate varies between 60% and 90%. Drug resistance and recurrence are commonly seen with incomplete and interrupted treatment.





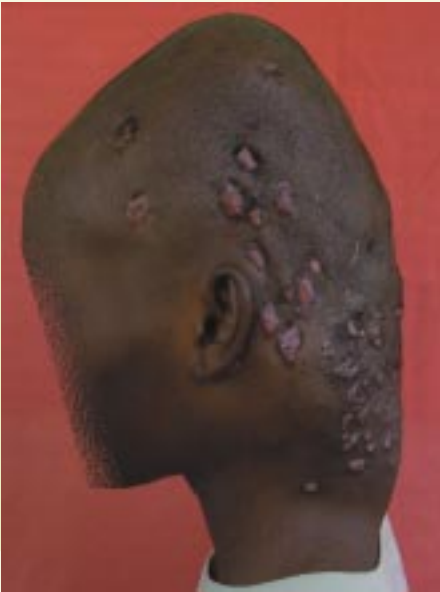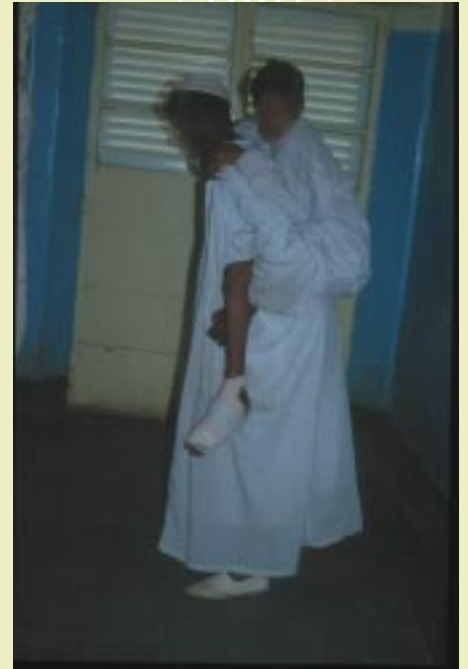Mycetoma in the Sudan

*Distribution Map Showing
Mycetoma Endemic Areas*

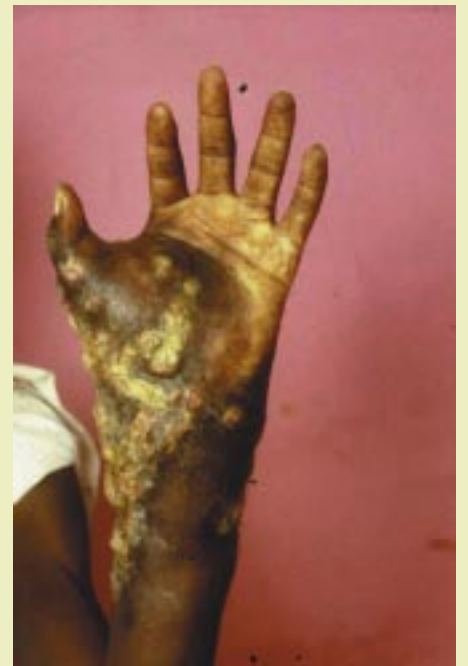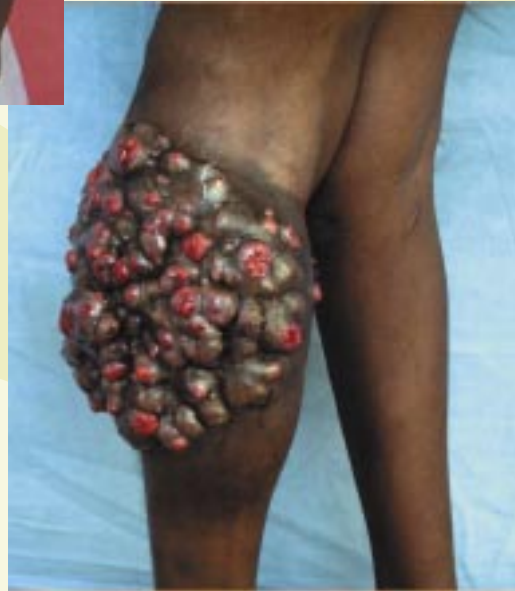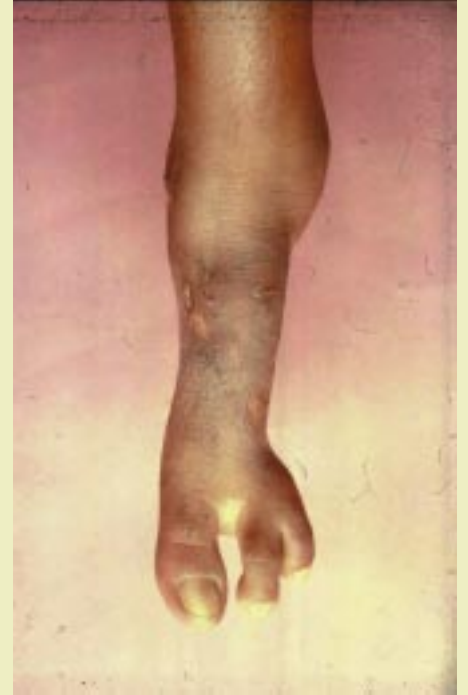*A Field Trip to the
Land of Mycetoma*

10





note that faces have been distorted purposefully to become unidentifiable to preserve patient identity and privacy



Mycetoma

Is Not Just the Foot

Treatment of Eumycetoma

The common drugs regimes are:

1- Ketoconazole: the dose is 400-800 mg daily. The cure rate seemed to be dose dependent.

2- Itraconazole: has a good success and low recurrence rate. Patients showed good clinical response to 400 mg itraconazole daily.

Treatment of these patients may continue for periods ranging from few to many years. The liver function of the patients should be checked before and during treatment as these drugs may affect the liver.

The treatment is usually stopped with clinical, serological, radiological and ultrasonic cure. The criteria for cure are:

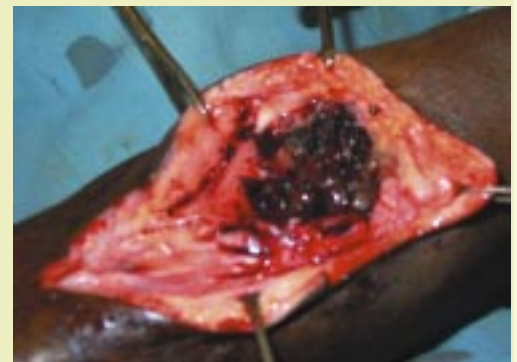- 1: Disappearance of the subcutaneous mass, healing of the sinuses and the skin return to normal.
- 2: Three consecutive negative CIE tests one month apart.
- 3: The bone regains its normal radiological appearance with remodeling.
- 4: The absence of hyperreflective echoes and cavities on ultrasonic examination.
- 5: No grains are seen in FNA.



Surgery for Mycetoma

The goal of surgery in mycetoma is complete removal of the lesion or the reduction of size followed by medical treatment. Local anaesthesia is contra-indicated as the extent of the disease is always difficult to ascertain preoperative. Eumycetoma is well-encapsulated and great care must be exercised not to rupture the capsule, which may lead to recurrence by transferring the fungal element into other parts of the operative field. Actinomycetoma has an ill-defined border; therefore a margin of healthy tissue should always be excised with the lesion. Simple bone curettage and soft tissue excision is recommended for localised bony lesions. A bloodless operative field using a tourniquet is mandatory to identify margins of the lesion. It is advisable to flood the wound at the end of surgery with tincture of iodine to destroy any missed grains. The wound can be closed primarily and in many cases, skin grafts may be required. The open postoperative wounds are usually dressed with 2% iodine in glycerin to destroy any fungal elements. In postoperative dressing normal saline and Eusol solution can be used but they have no advantage over the others.

In advanced cases of mycetoma not responding to medical treatment for a prolonged period nothing short of amputation is likely to succeed. Extensive repeated excisions of the diseased tissue, including bone may be carried out several times to avoid the social consequences of amputation. This debulking procedure must be coupled with chemotherapy. In less advanced cases less mutilating surgery is advised for example, toe, mid tarsal or Syme's amputation. However, in many cases of inadequate surgery recurrence is inevitable.



Evidence-based Recommendations for the Workup of Patients with Mycetoma

Diagnosis can be established by:

- ✓ *Good clinical interview*
- ✓ *Through loco-regional and general clinical examination*
- ✓ *X-Ray of the affected part in antero-posterior and lateral views*
- ✓ *Ultrasonic examination of the affected part*
- ✓ *FNA from the lesion*

Surgical biopsy is performed under general or spinal anaesthesia with a tourniquet. The biopsy specimen is divided into two parts, one part is sent in a sterile container for culture and one is fixed in 10% formal saline for histopathological examination.

Medical treatment

For actinomycetoma it is recommended to start with the following regimen:

Streptomycin sulphate (14 mg/kg daily) intramuscular daily for four weeks then on alternate days, and Diaminodiphenyl sulphone (dapson) (1.5 mg/kg twice daily).

If there is no response after a few months or if there are persistent side effects then dapson is replaced by Co-trimoxazole (14 mg/kg twice daily) or Rifampicin (15-20 mg/kg daily). For massive lesions Co-trimoxazole, rifampicin and Streptomycin sulphate can be combined together.

For eumycetoma the following is recommended:

1- Ketoconazole: the dose is 400-800 mg daily.

2- Itraconazole: the dose is 400 mg daily.

Treatment of mycetoma patients may continue for periods ranging from few to many years. The liver functions of the patients should be checked before and during treatment as some of these drugs are hepatotoxic. The treatment is usually stopped with clinical, serological, radiological and ultrasonic cure.

In all patients the medical is stated before surgery and continued postoperatively to avoid recurrence.

Surgical treatment:

Surgical excision is recommended for small localized lesions, debulking of massive lesions; for better response to medical treatment and for lesions became well encapsulated by medical treatment.

Amputation rarely done nowadays. It is done for very advanced lesions with bad general condition and as a life saving procedure.


Follow up

Every eight week if possible for assessment of treatment and cure and for early detection of recurrence. Frequent check x-ray, full blood count and liver functions are recommended for patients on medical treatment.

Further Reading

01. Fahal AH, Hassan MA. Mycetoma. *British Journal of Surgery*. 1992; 79(11): 1138-1141.
02. Fahal AH, Suliman SH, Gadir AFA, EL Hag IA, EL Amin FI, Gumaa SA, Mahgoub ES. Abdominal wall mycetoma: an unusual presentation. *Transactions of the Royal Society of Tropical Medicine and Hygiene*. 1994; 88: 78-80.
03. Fahal AH, Suliman SH. Clinical presentation of mycetoma. *Sudan Medical Journal*. 1994; 32: 46-66.
04. Fahal AH, EL Toum EA, EL Hassan AM, Gumaa SA, Mahgoub ES. A preliminary study on the ultrastructure of *Actinomyces pelletieri* and its host tissue reaction. *Journal of Medical and Veterinary Mycology*. 1994; 32: 343-348.
05. EL Hassan AM, Fahal AH, EL Hag IA, Khalil EAG. The pathology of mycetoma: Light microscopic and ultrastructural features. *Sudan Medical Journal*. 1994; 32: 23-45.
06. Fahal AH, Hassan MA, Sanhoury M. Surgical treatment of mycetoma. *Sudan Medical Journal*. 1994; 32: 98-104.
07. Fahal AH, EL Toum EA, EL Hassan AM, Gumaa SA, Mahgoub ES. Host tissue reaction to *Madura mycetomatis*: New classification. *Journal of Medical and Veterinary Mycology*. 1995; 33: 15-17.
08. EL Hag IA, Fahal AH, Khalil EAG. Fine needle aspiration cytology of mycetoma. *Acta Cytologica*. 1996; 40(3): 461-464.
09. Fahal AH, Omer, SM, El Razig SA, Ali ABE, Mahdi EMA, Mahgoub ES. Thyroid function in mycetoma patients. *East African Medical Journal*. 1995; 72(7): 454-456.
10. Fahal AH, Azziz KAA, Suliman SH, Galib HV, Mahgoub ES. Dual infection with mycetoma and tuberculosis. *East African Medical Journal*. 1995; 72(11): 749-750.
11. Mohamed ARO, Fahal AH, Venge V. Immunoglobulin and inflammatory markers profile in mycetoma. *East African Medical Journal*. 1996; 73(4): 212 (Letter).
12. Fahal AH, Yagi HI, EL Hassan AM. Mycetoma induced palatal deficiency and pharyngeal plexus dysfunction. *Transactions of Tropical Medicine and Hygiene* - 1996; 90: 676-677.
13. Fahal AH, Sheikh HE, EL Hassan AM. Pathological fracture in mycetoma. *Transactions of Tropical Medicine and Hygiene* - 1996; 90: 675-676.
14. Fahal AH, Sharfi, AR, Sheikh HE, EL Hassan AM. Mycetoma: Uncommon complication. *Transactions of Tropical Medicine and Hygiene*. 1996; 89: 550-552
15. Fahal AH, Sadig ME, Suliman SH, EL Razig SA, Mahgoub ES. Lack of association between ABO blood groups and Rh factor and the tendency to develop mycetoma. *East African Medical Journal* - 1996; 11: 769. (Letter).
16. Fahal AH, EL Hag IA, Gadir AFA, EL Lider AR, EL Hassan AM. The blood supply and vasculature in mycetoma. *Journal of Medical and Veterinary Mycology* - 1997; 35: 101. 106.
17. Fahal AH, Sheikh HE, EL Lider MA, Homeida MA, EL Arabi YE, Mahgoub ES. Ultrasonic imaging in mycetoma. *British Journal of Surgery* - 1997; 78: 765-766.
18. Ahmed AOA, Fahal AH, Abugroun EAM, Zijlstra E, Belkum A van, Verbrugh HA. Unexpected high prevalence of secondary bacterial infection in mycetoma. *Journal of Clinical Microbiology*. 1998;

19. Fahal AH, Sharfy ARA. Vulval mycetoma: a rare cause of bladder outlet obstruction. *Transactions of Tropical Medicine and Hygiene*. 1998; 92: 652-653.
20. Ahmed AO, Mukhtar MM, Kools-Sijmons M, Fahal AH, de Hoog S, van den Ende BG, Zijstara EE, Verburgh H, Abugroun ESA, EL Hassan AM, Van Belkum A. Development of a species-specific PCR RFLP procedure for the identification of *Madurella mycetomatis*. *Journal of Clinical Microbiology* 1999; 37(10):3175-8.
21. Fahal AH. The management of mycetoma. *Post-Graduate -Caribbean*. 2000;5:
22. EL Hassan AM, Fahal AH, Ahmed AO, Ismail A, Veress B. The immunopathology of actinomycetoma lesions caused by *streptomyces somaliensis*. *Transaction of the Royal Society of Tropical Medicine and Hygiene*. 2001 Jan-Feb; 95(1): 89-92.
23. Ahmed A.O.A., Adelmann D, Fahal A.H., Verbrugh H.A., Van Belkum A., De Hoog S. Environmental occurrence of *Madurella mycetomatis*, major agent of human eumycetoma in Sudan. *Journal of Clinical Microbiology*. 2002 40(3): 1031-1036
24. Fahal AH, Rahman I A, El-Hassan AM, Zijlstra EE The efficacy of itraconazole in the treatment of patients with eumycetoma due to *Madurella mycetomatis* (In press).
25. Fahal AH, EL Sheik H, El Hassan AM. Venous Varicosity In Mycetoma (In press)
26. Ahmed AOA, Van Belkum A, Vossenbelt P, Ott A, Zijlstra EE, Fahal A, Sonneveld P, Verbrugh HA. Differential serum levels of basic fibroblast growth factor for patients with various grades of *Madurella mycetomatis* infection. (In press).
27. Mahgoub ES,. Murray IG. Mycetoma. London. William Heinemann. Medical Books. pp. 2-25. 1973.
28. Murray IG. Report to the Medical Research Council on a visit to Sudan. 1960.
29. EL Moghraby IM. Mycetoma in Gezira. *Sudan Medical Journal*. 1971; 9: 77.
30. Mahgoub ES. Experimental infection of athymic nude New Zealand mice "Nu-Nu" strain with mycetoma agents. *Sabouraudia*. 1978; 16: 211-216.
31. Abbott PH. Mycetoma in the Sudan. *Transactions of the Royal Society of Tropical Medicine and Hygiene*. 1956; 50: 11-24.
32. Lynch JB. Mycetoma in the Sudan. *Annual of the Royal Collage of surgeons of England*. 1964; 35: 319-340.
33. Mahgoub ES. Mycoses in the Sudan. *Transactions of the Royal Society of Tropical Medicine and Hygiene*. 1977; 71: 184-188.
34. Mahgoub ES. Mycetoma. *Tropical Doctor*. 1974;4:48.
35. Mahgoub ES. Clinical aspects of mycetoma. *Systemic mycoses. A Ciba Foundation Symposium*. J & A. Churchill Ltd. London. 1968; pp 125-127.
36. Grantham-Hill C. Some clinical observations on mycetoma. *Transactions of the Royal Society of Tropical Medicine and Hygiene*. 1931; 25: 39-48.
37. Gumaa SA. Mycetoma. *Post-Gradate Doctor, Middle East*. 1983; 6: 15-20.
38. EL Hassan AM, Mahgoub ES. Lymph nodes involvement in mycetoma.



Transactions of the Royal Society of Tropical Medicine and Hygiene. 1972; 66: 165-169.

39. Gumaa SA, Mahgoub ES, EL Sid MA. *Mycetoma of the head and neck. American Journal of Tropical Medicine.* 1986; 35(3): 596-600.
40. EL Bashir EI, Idris AM, Gumaa SA, Mahgoub ES. *Actinomycetoma of the mandibular region causing ankylosis. British Journal of Oral and Maxillofacial Surgery.* 1987; 25: 256-260.
41. Gumaa SA, Sattir AA, Shehata AH, Mahgoub ES. *Tumor of the mandible caused by *Madurella mycetomi*. American Journal of Tropical Medicine and Hygiene.* 1975; 24(3): 471-474.
42. Yousif MA, Hay RJ. *Leucocyte chemotaxis to mycetoma agents. The effect of the antifungal drugs griseofulvin and ketoconazole. Transactions of the Royal Society of Tropical Medicine and Hygiene.* 1987; 81(2): 319-321.
43. Nasher M, Wethered D, Hay RJ, Mahgoub ES, Gumaa SA. *The ultrastructure of actinomycetoma grains caused by *streptomyces somaliensis*. American Journal of Tropical Medicine and Hygiene.* 1987; 37: 174-179.
44. Mahgoub ES. *Mycetoma caused by *Curvularia lunata*, *Madurella grisea*, *Aspergillus nidulans* and *Nocardia brasiliensis* in Sudan. Sabouraudia.* 1973; 11: 179-182.
45. Mahgoub ES, Yacoub AAA. *Primary actinomycosis of the foot and the leg; Report of a case. Journal of Tropical Medicine and Hygiene.* 1968; 71: 256-258.
46. Mahgoub ES. *Serological diagnosis of mycetoma. Mycoses. Pan American Health Organization. Scientific publication No. 304, Washington, D.C.*
47. Murray IG, Moghraby IE. *The value of skin tests in distinguishing between maduromycetoma and actinomycetoma. Transactions of the Royal Society of Tropical Medicine and Hygiene.* 1964; 58(6): 557-559.
48. Mahgoub ES. *The value of gel diffusions in the diagnosis of mycetoma. Transactions of the Royal Society of Tropical Medicine and Hygiene.* 1964; 58(6): 560-563.
49. Mahgoub ES, Gumaa SA, EL Hassan AM. *Immunological status of mycetoma patients. Bull Soc Path Exo.* 1977; 70(1): 48-54.
50. Gumaa SA, Mahgoub ES. *Evaluation of the complement fixation test in the diagnosis of Actinomycetoma. Journal of Tropical Medicine and Hygiene.* 1973; 76: 140-142.
51. Gumaa SA, Mahgoub E.S. *Counter-immuno-electrophoresis in the diagnosis of mycetoma and its sensitivity compared to immunodiffusion. Sabouraudia.* 1975; 13: 309-315.
52. Taha A. *A serological survey of antibodies to *Streptomyces somaliensis* and *Actinomyces madurae* in the Sudan using enzyme linked immunosorbent assay and immunoblotting. Transactions of the Royal Society of Tropical Medicine and Hygiene.* 1983; 77: 49-50.
53. Wethered DB, Markey MA, Hay RJ, Mahgoub ES, Gumaa SA. *Humoral immune responses to mycetoma organism: Characterization of specific antibodies by the uses of enzyme - linked immunosorbent assay and immunoblotting. Transactions of the Royal Society of Tropical Medicine and Hygiene.* 1988; 82: 918-923.
54. Mahgoub ES. *Experimental infection of athymic nude New Zealand mice "NU-NU" strain with mycetoma agents. Sabouraudia.* 1978;

16: 211-216.

55. Gumaa SA, Mohamed FHA, Mahgoub ES, Adam SEI, EL Hassan AM, Imbabi SE. Mycetomas in goats. *Sabouraudia*. 1978; 16: 217-223.
56. Mahgoub ES. Medical management of mycetoma. *Bull. WHO*. 1976; 54: 303-310.
57. Mahgoub ES. Treatment of actinomycetoma with sulphamethoxazole plus trimethoprim. *American Journal of Tropical Medicine and Hygiene*. 1972; 21(3): 332-335.
58. Mahgoub ES. Mycetoma. *Seminars in Dermatology* 1985; 4: 230.
59. Mahgoub ES, Gumaa SA. Ketoconazole in the treatment of eumycetoma due to *madurella mycetomi*. *Transactions of the Royal Society of Tropical Medicine and Hygiene*. 1984; 78: 376-379.
60. Wethered DB, Markey MA, Hay RJ, Mahgoub ES, Gumaa SA. Ultrastructural and immunogenic changes in the formation of mycetoma grains. *Journal of Medical and Veterinary Mycology*. 1986; 25(1): 39-46.
61. Gumaa SA, Abu Samra MT. Experimental mycetoma infection in the goat. *J Comp Pathol*. 1981; 91(3): 341-346.
62. Nasher MA, Hay RJ, Mahgoub ES, Gumaa SA. In-vitro studies of antibiotics sensitivities of *Streptomyces somaliensis*, a cases of human actinomycetoma. *Transactions of the Royal Society of Tropical Medicine and Hygiene*. 1989; 83: 265-268.
63. Batul MA, AL Asha, Fati EA, Mohamed EA, Isam ET, Gumma SA, Mahgoub ES. Natural *Madurella mycetomatis* infection in a donkey. *Journal of Equine Veterinary*.
64. Chalmers AJ, Archibald RG. The Sudanese maduromycosis." *Annals of Tropical Medicine and Parasitology*. 1916; 10: 169-223.
65. Chalmers AJ, Christopherson JB, A Sudanese Actinomycosis. *Annals of Tropical Medicine*. 1916; 10: 224-282.
66. Chalmers AJ, Archibald RG. The classification of mycetoma. *Journal of Tropical Medicine and Hygiene*. 1918; 21 :121-123.
67. Mahgoub ES. Clinical aspects of mycetoma. A Ciba Foundation Symposium. J & A. Churchill Ltd. London. 1968; pp 125-127.



*Evidence-Based Guidelines
for the Management of
Mycetoma Patients*

**Published by the
Mycetoma Research Center
Khartoum - Sudan**

October 2002



*A Natural
Mycetoma Habitat*

*Layout and Presentation by
Abdelrahman S-E Imbabi, FRCSEd
October 2002*

[View publication stats](#)